

LYMPHOMA IN AN HIV-POSITIVE PATIENT

Carmen Manciu¹, Carmen Dorobăț¹, C. Dănăilă¹, Maria Alexandra Largu²

University of Medicine and Pharmacy "Grigore T. Popa" - Iasi
Faculty of Medicine

1. Department of Medical Specialties (II)

2. Department of Preventive Medicine and Interdisciplinarity

LYMPHOMA IN AN HIV-POSITIVE PATIENT (Abstract): HIV/AIDS is considered to be revealing of oncological diseases, of which most frequent are lymphomas. The main causes for this type of disease are non-adherence and non-compliance to antiretroviral therapy (ART). We are hereby presenting a clinical case of lymphoma in an HIV-infected adult, with non-adherence for 30 months. In such a case the interdisciplinary collaboration with the hematologist was essential for the patient's survival. **Keywords:** HIV/AIDS, LYMPHOMA, ANTIRETROVIRAL THERAPY, ADHERENCE.

The HIV pandemic is a reality that is increasingly frequent in Romania. Studies have observed that the median age of HIV-positive patients has slowly shifted from the "pediatric cohort" (born in '87-'89) to adults and even patients over 60 years old (1).

Frequent cases of cancer are observed in patients with severe immunosuppression. Lymphomas are dominant in literature and they require a combined therapy and monitoring by both the infectious diseases doctor and the oncologist (2).

CASE PRESENTATION

We aim to present the case of a patient born in 1979, diagnosed in 2010 (31 years old) with pulmonary tuberculosis. We used two specific tests to screen for HIV: the enzyme-linked immunosorbent assay (ELISA) and antigen-antibody confirmation test Western Blott. They both were positive. At the very beginning, CD4 cell count was 120/mm³ and viral load (VL) 742000 cop-

ies/mm³ (fig. 1). We applied therapeutic protocol, initiating therapy with tuberculostatics for 10 days. Next we started antiretroviral therapy with zidovudine and lamivudine (AZT+3TC) and efavirenz (EFV). To avoid the immune reconstruction syndrome we administered dexamethazone.

Serology for hepatitis B and C were negative, as well as syphilis. Acute phase reactants for cytomegalovirus and toxoplasma were also negative. The resistance report for antiretroviral drugs was negative for all antiretroviral (ART) classes. However, we identified 2 minor mutations: L10V for protease inhibitors and K103R for non-nucleosidic reverse-transcriptase inhibitors. We also started prophylaxis for pneumocystosis.

The patient's evolution was favorable. In February 2011 (6 months after diagnosis), CD4 had increased to 414 cells/mm³ and the viral load decreased to 160 cop-

ies/mmc.

The patient ended treatment with tuberculostatics after one year, but adherence to ART decreased, up until VL=99900 copies/mmc and CD4=251 cells/mmc in Nov 2012 (fig. 1).

We lost track of the patient for 30 months. In June 2014 the patient presents herself to the Infectious Diseases Hospital with a massive clinical deterioration, with wasting syndrome, losing over 15 kg in body mass. Also important generalized edema, hypoproteinemia 41.6 g/l, hemoglobin 2.7 g/l, white blood cells 2800/mmc and mononucleosic syndrome present; CD4=58 cells/mmc and VL=54300 copies/mmc (fig. 1). Pulmonary radiological imaging revealed a small amount of pleural liquid, arising the suspicion for pulmonary tuberculosis. This is why our option for antiretroviral therapy consisted of raltegravir (RAL) with abacavir+ lamivudine (KVV) (RAL+KVV), avoiding protease inhibitors. Sputum samples were negative for Koch bacillus (BK) bacterioscopy.

We started support therapy with blood derivates, intravenous aminoacids, albumin, filgastrinum, cotrimoxazol for pneumocystosis prophylaxis and fluconazol for

oral candidiasis.

The patient is released from the hospital after 33 days of hospitalization; biological parameters were much improved – white blood cells 3000/mmc, a normal proteinemia 64.5 g/l, and hemoglobin 9.1 g/l. The patient also gained 4 kg in weight. Renal and hepatic functions were normal.

For the whole duration of the hospital stay, the patient had psychological evaluation and regular counseling sessions. This improved her self-esteem and self-worth, which motivated her to decide for a better adherence to antiretroviral therapy. Through specific techniques (3), the psychologist encouraged the patient to take responsibility for her health-related behavior, thus changing her lifestyle as well.

Two months later, the patient is admitted again with fever and swallowing of latero-cervical lymph nodes. BK cultures were negative, which allowed a switch to last generation antiretroviral molecules – boosted darunavir (DRV/r), etravirine (ETV), abacavir+lamivudine (KVV).

The node biopsy showed mixed cellularity Hodgkins lymphoma; CD4=82 cells/mmc, VL=80 copies/mmc (very close to non-detectable) (fig. 1).

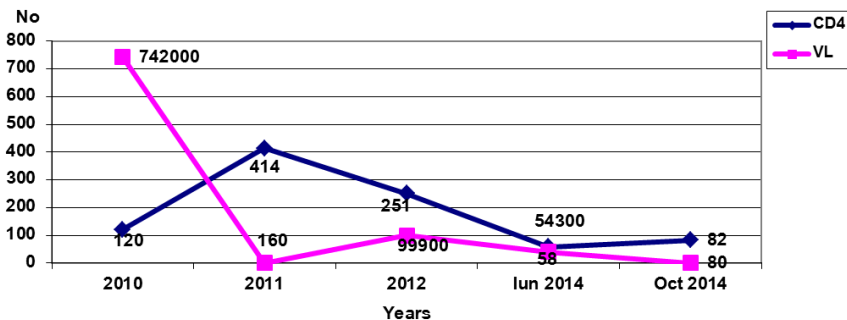


Fig. 1. CD4 cell count and viral load

The clinical and biological aspect of this patient allowed chemotherapy in repeated rounds, but in the presence of substitutive

support (blood derivates, filgastrinum, intravenous aminoacids, and albumin).

Latero-cervical lymph nodes decreased

in size. Antiretroviral therapy was continued until present day, keeping this ART scheme for the rest of her life.

DISCUSSION

Immunosuppression with values of $CD4 < 200/mm^3$ is manifested in patients that are non-adherent, non-compliant to ART, in cases of therapeutic fatigue and acquired resistance to highly active antiretroviral therapy (HAART). The Romanian cohort has an extended experience with antiretroviral therapy; patients are multi-experimented and have a history of antiretroviral regimens from the first PIs to last generation molecules (4). The cancer incidence in HIV-positive patients decreased dramatically after 1990, along with the HAART era (5).

From an epidemiological point of view, the risk factors for lymphoma in the United States of America are sex, age and socio-economical status; 80% of people with non-Hodgkin lymphoma are men who have sex with men (MSM) and bisexuals. The high incidence in the East Coast is a reflection of HIV incidence (6).

One of the most significant differences in lymphomas occurring among HIV-infected individuals is a high association with oncogenic herpes viruses. There is a molecular heterogeneity of HIV-related lymphomas. From a pathogenic point of view, this includes mono- or polyclonal subtypes, the presence or absence of the Epstein-Barr virus (EBV) genome and

herpes virus 8 genome, which is integrated in the genome of the host cell. The roles of cytokines and tumor suppression genes, as well as the uncontrolled growth of B lymphocytes, are to be further researched. The main hypothesis is that, in the context of HIV immunosuppression, the EBV infection leads to a polyclonal stimulation and the immortalization of B cell clones (7).

Specific antiretroviral therapy is one of the pillars in sustaining the clinical and biological status of the patient, alongside support therapy. A high level of CD4 and a low viral load, as well as balanced biological parameters, assure a better response to specific chemotherapy in lymphomas (8).

CONCLUSIONS

The present case has revealed the importance that adherence to antiretroviral therapy has in the control of the HIV infection. This allowed the possibility to administer full-dose-intensive chemotherapy regimens with improved patient outcomes.

We found that it is essential that the infectious diseases doctor and the hematologist work together to ensure the best therapeutic solutions to support the HIV patient with lymphoma.

Psychological support and motivational psychotherapy have also been essential in sustaining this patient's desire to go through with therapy. It improved adherence to therapy and generated a change in the patient's lifestyle, as well as a sustained self-esteem and self-worth.

REFERENCES

1. Jallow A, Ljunggren G, Wändell P, Carlsson AC. Prevalence, incidence, mortality and co-morbidities amongst human immunodeficiency virus (HIV) patients in Stockholm County, Sweden - The Greater Stockholm HIV Cohort Study. *AIDS Care*. 2014;1-8.

2. Cobucci RN, Lima PH, de Souza PC, Costa VV, Cornetta MD, Fernandes JV, Gonçalves AK. Assessing the impact of HAART on the incidence of defining and non-defining AIDS cancers among patients with HIV/AIDS: A systematic review. *J Infect Public Health*. 2015; 8(1): 1-10
3. Manciu C, Dorobat C, Astărăstoae V, Largu MA. The HIV-positive patient in intensive care – psychological profile, *Rev Med Chir*, 2014; 118(3): 738-743.
4. Manciu C, Largu MA, Vătă, A, Nicolau C., Prisăcariu L, Stoica D, Dorobăț C. Calitatea vietii la pacientii Centrului Regional HIV/SIDA din Iasi. *Rev Med Chir*. 2011; 115(4): 1214-1218.
5. Csarman E. Pathology of lymphoma in HIV. *Curr Opin Oncol* 2013; 25(5): 487–494.
6. Jacobson CA, Abramson JS. HIV-Associated Hodgkin's Lymphoma: Prognosis and Therapy in the Era of cART. *Advances in Hematology*. 2012: 507257. doi: 10.1155/2012/507257. Epub 2012 Jan 5
7. Carbone A, Gloghini A, Serraino D, Spina M. HIV-associated Hodgkin lymphoma. *Curr Opin HIV AIDS* 2009; 4(1): 3-10.
8. Le Moal G, Prazuck T, Saberan-Roncato M, Julien J, Padeloup T, Descamps JM, Lestelle M, Arsac P, Champeaux-Orange E, Bouaraba L, Hocqueloux L. Immuno-virological and clinical impacts of treating cancer in patients living with HIV. *J Antimicrob Chemother* 2015; 70(1): 249-256

NEWS

A MIXTURE OF CHIA SEED AND POMEGRANATE FRUIT EXTRACTS-SYNERGISTIC EFFECT ON INHIBITION OF MELANIN BIOSYNTHESIS

Fatty acids (especially omega-3 and omega-6) have not only nutritional benefits, but also cosmetic ones. They are involved in many biological functions in the skin (prevention of transepidermal water loss, maintenance of the *stratum corneum* epidermal barrier and disruption of melanogenesis in epidermal melanocytes). *Salvia hispanica* L. (commonly known as chia) seeds are used especially as dietary supplements due to their content in fatty acids and phenolic compounds. The consumption of the seeds decreases the triglyceride and blood glucose levels, thus reducing the risk of heart disease and obesity. *Punica granatum* L. (pomegranate) fruits, rich in polyphenols, have the capacity to reduce melanin content in the skin. Because chia seed oil (rich in α -linolenic and linoleic acids) has high viscosity, low solubility and poor cellular permeability, Diwakar *et al.* have tested a mixture of chia seed and pomegranate extracts (1:1) to reduce melanin content in Melan-a cell culture. The results demonstrated that a mixture containing 25 μ L of each extract reduced melanin production by 80% as compared to chia seed extract (10%) and pomegranate fruit extract (40%). The down-regulation of melanogenesis-related genes (Tyr, Tyrp1 and MC1r) could be a mechanism involved in melanin production inhibition, since the mixture did not inhibit tyrosinase activity. The study proved that the mixture of chia seed and pomegranate fruit extracts (1:1) had synergistic effect on melanin inhibition in Melan-a culture cells (Diwakar G, Rana J, Saito L, Vredeveld D *et al.* Inhibitory effect of a novel combination of *Salvia hispanica* (chia) seed and *Punica granatum* (pomegranate) fruit extracts on melanin production. *Fitoterapia* 2014; 97:164-171).

Cristina Lungu